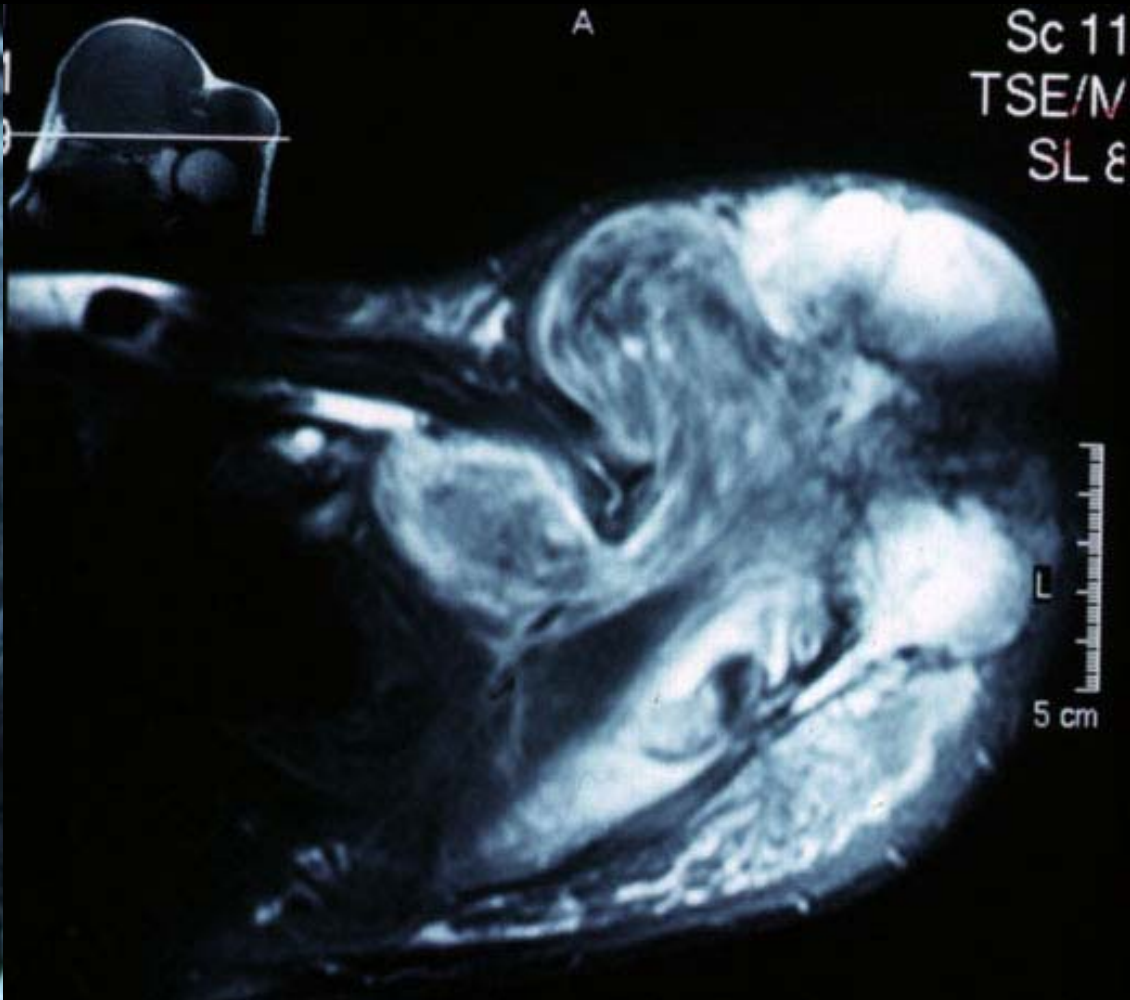
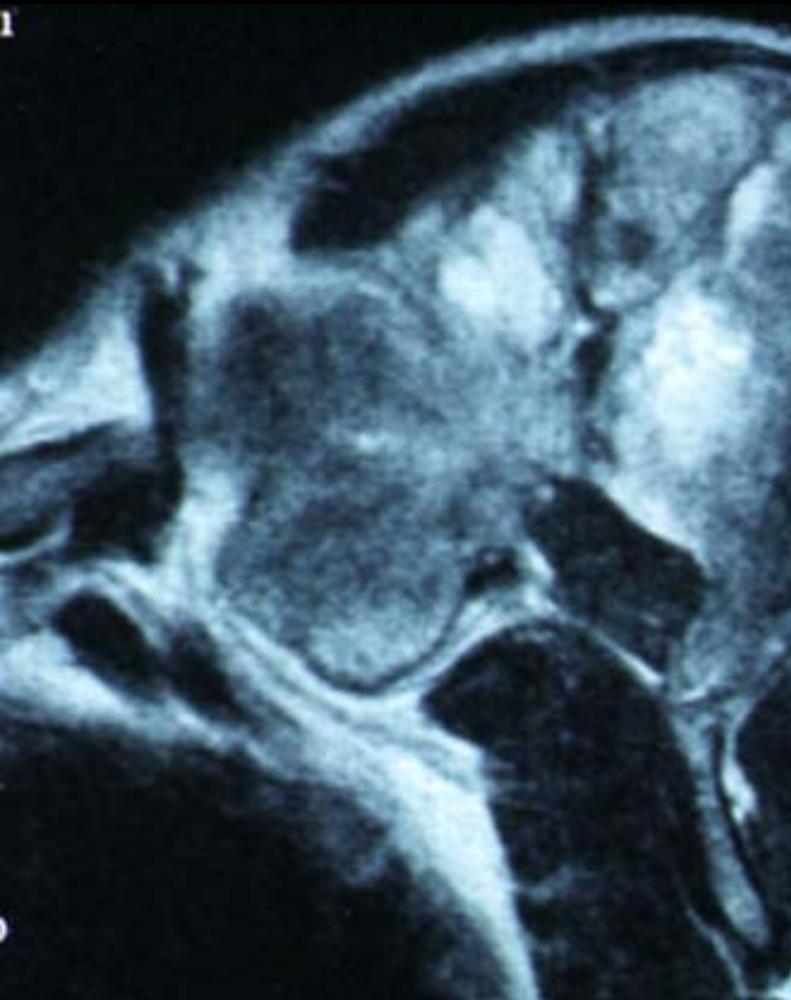
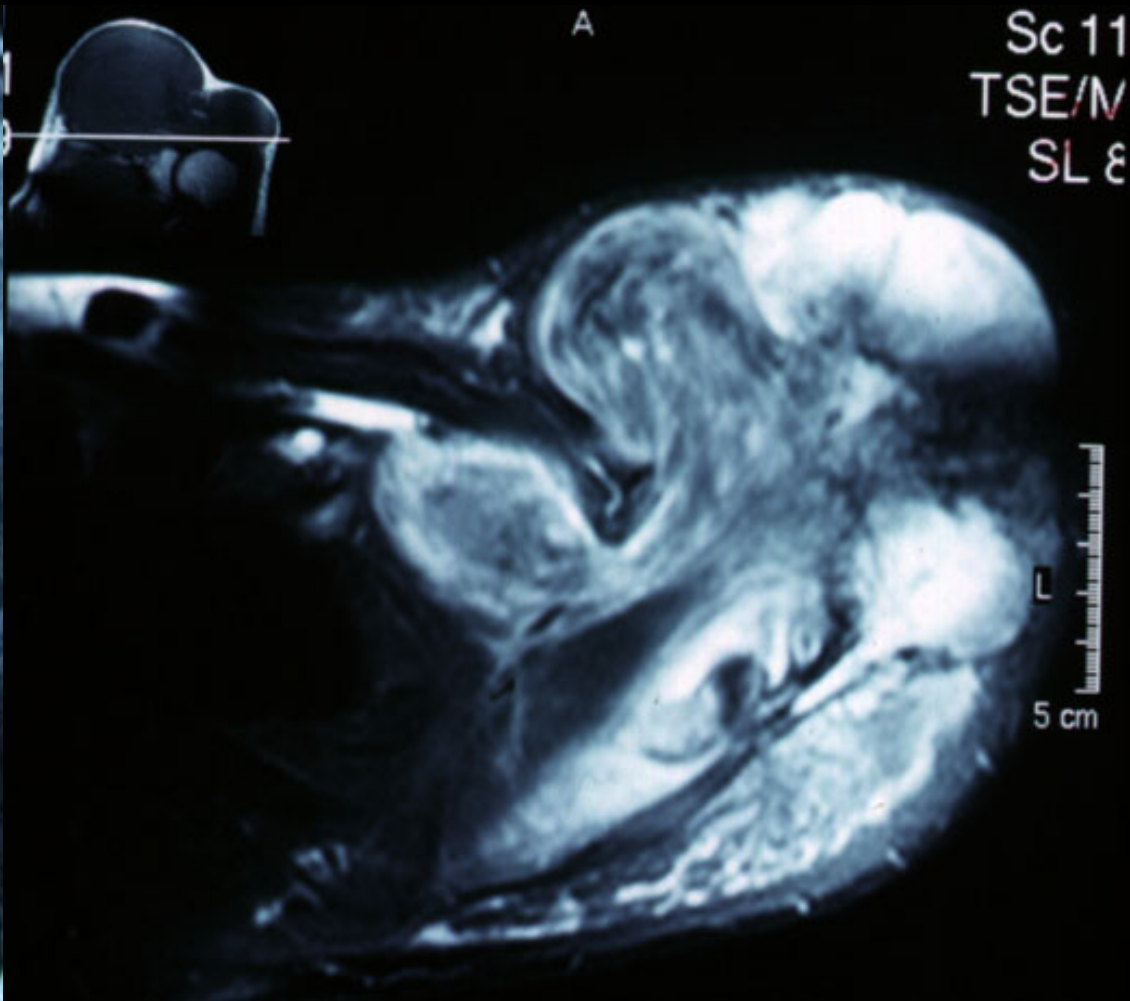
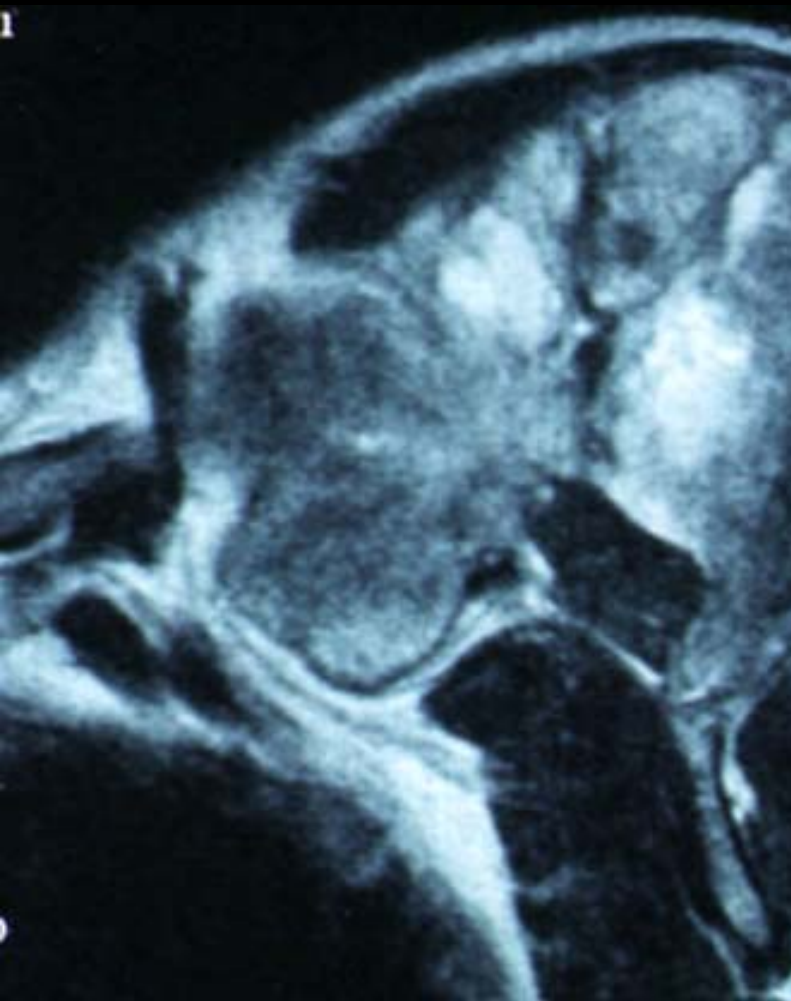
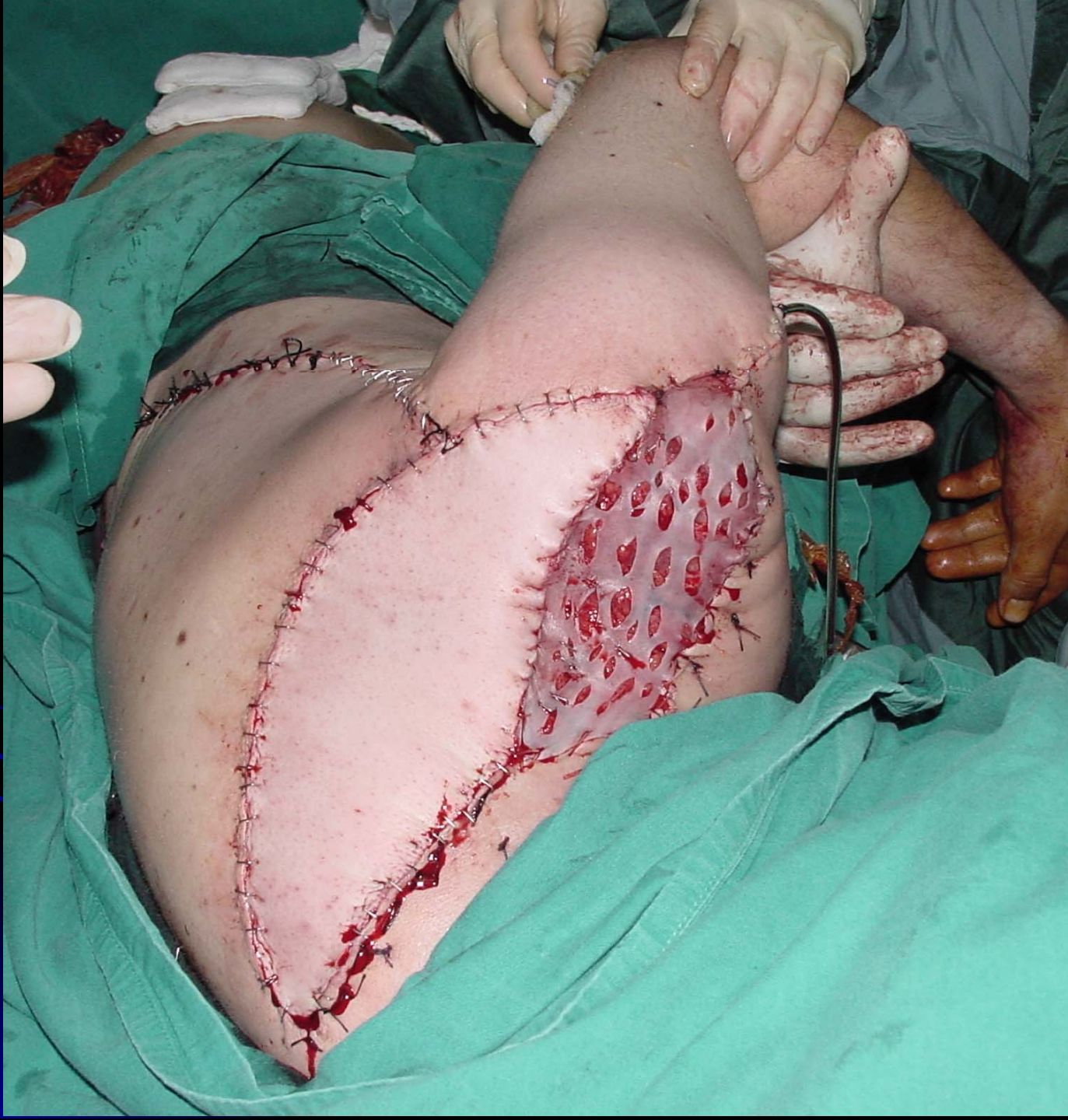


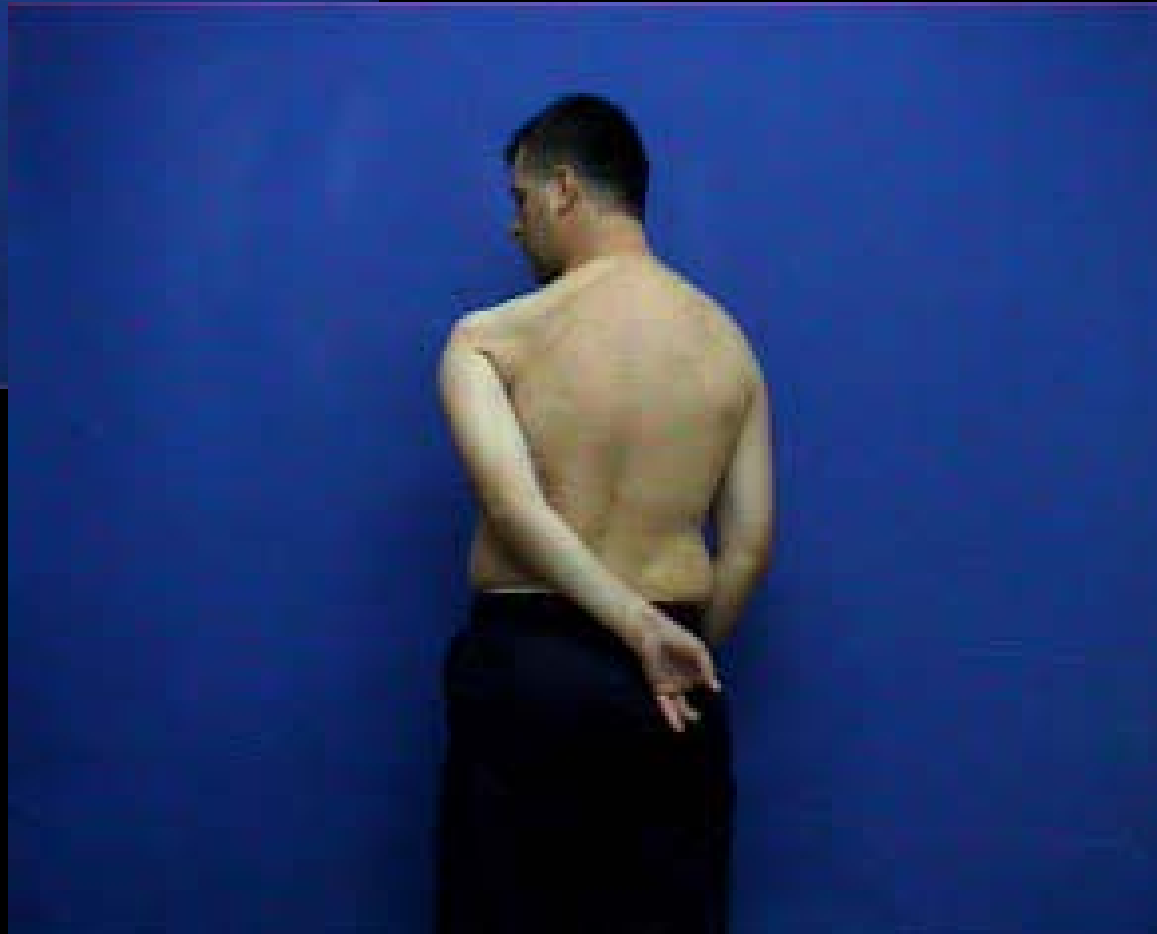
EKSTREMİTE KURTARICI CERRAHİDE EKSTREM UYGULAMALAR: *“Hayal gücü, bilgiyi zorlamalıdır?”*

H. Özger, L. Eralp, M. Topalan, K. Özkan



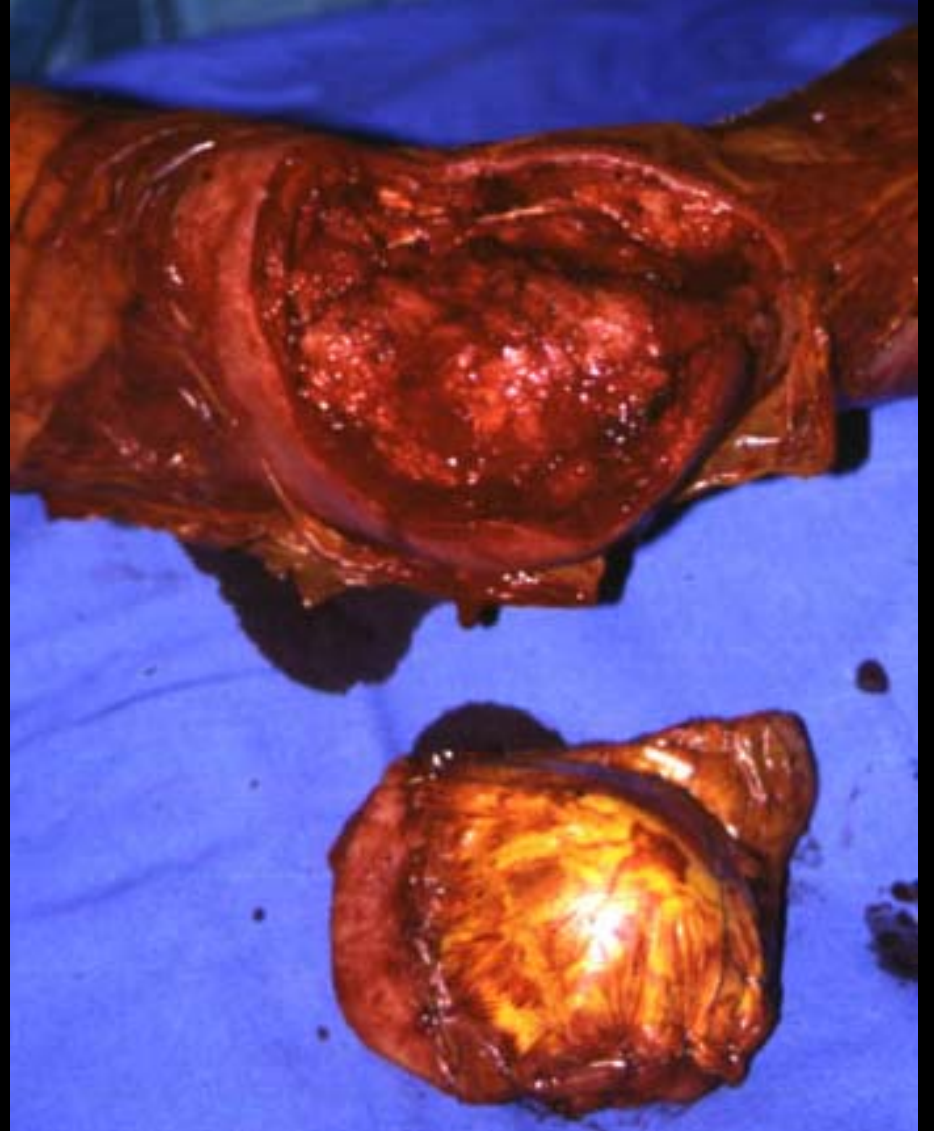






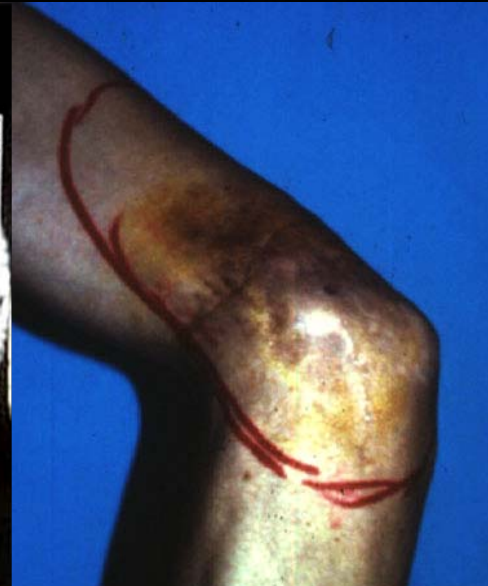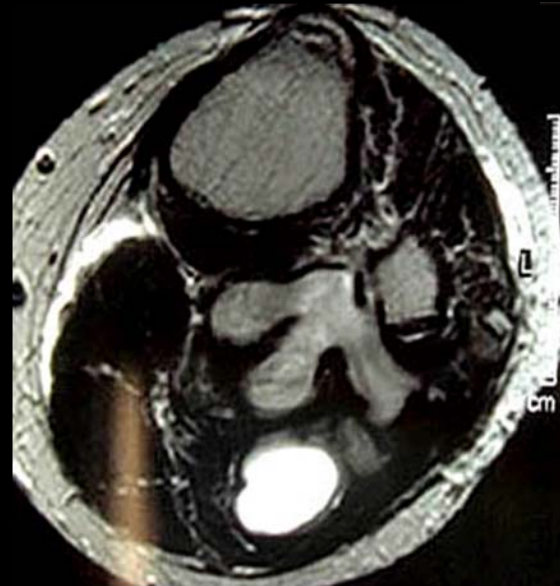
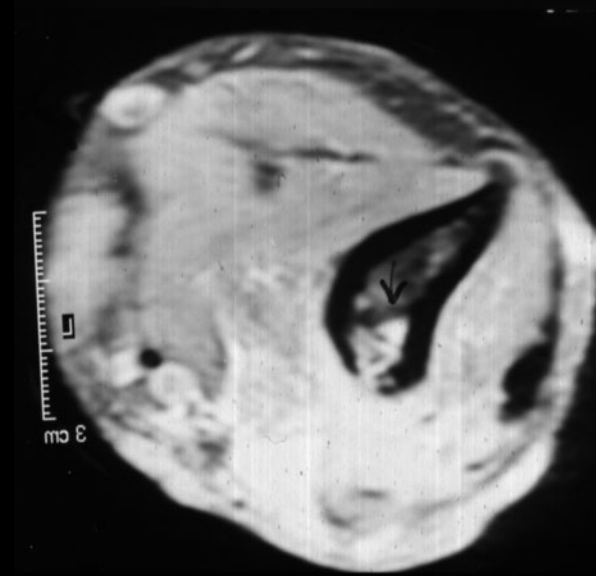
Hastalar ve Yöntem

- 1994 – 2001
- 22 hasta
- 13 E, 9 K
- Ortalama yaş 25.5
(14 – 68)
- Ortanca takip 42 ay
(16 – 98)
- Tümü IIB sarkom hastası



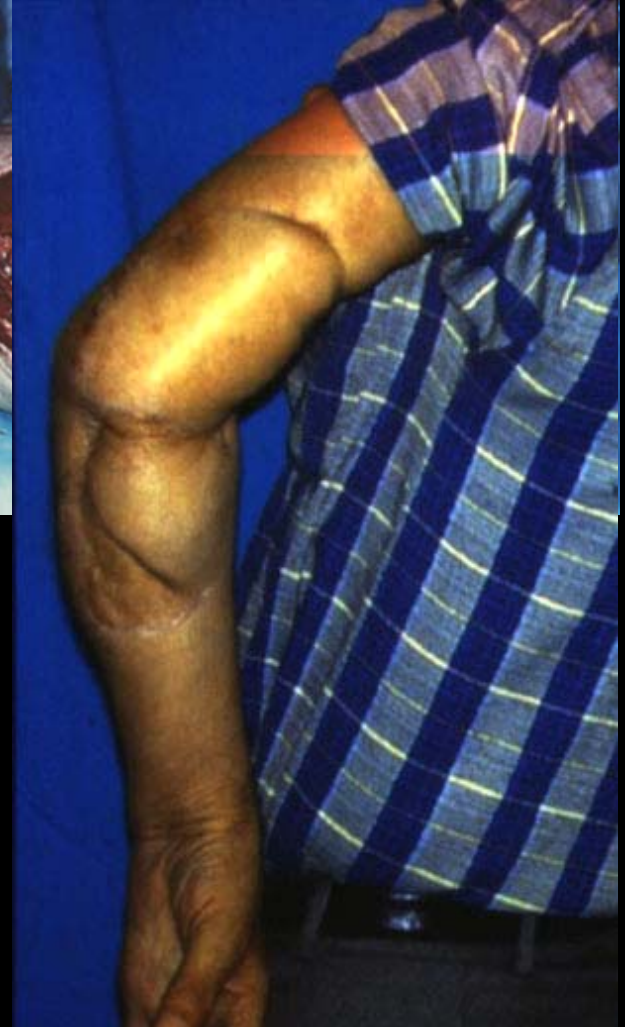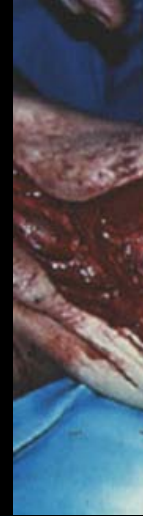Hastalar ve Yöntem

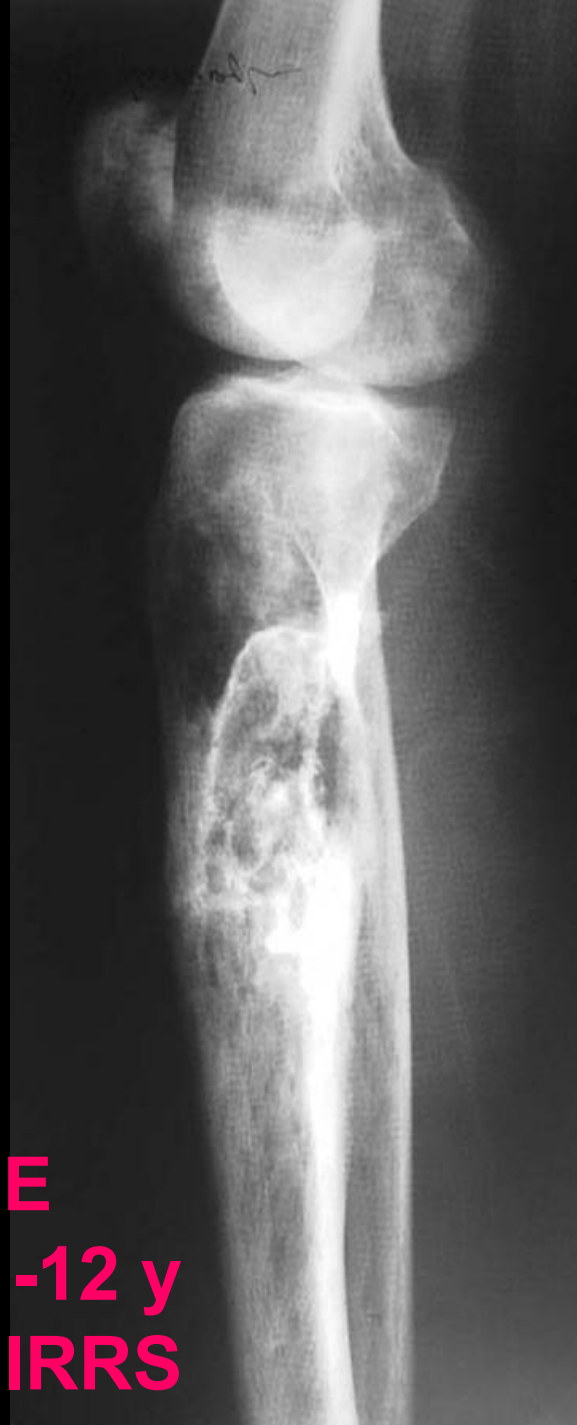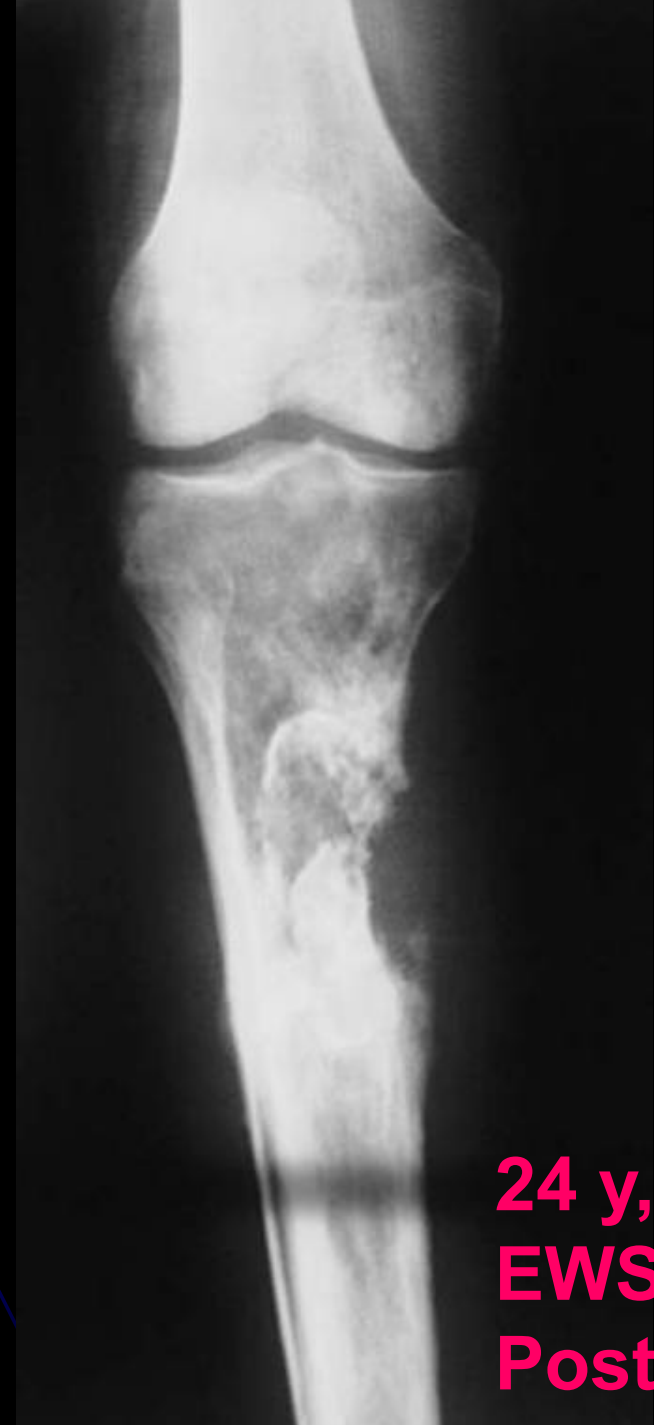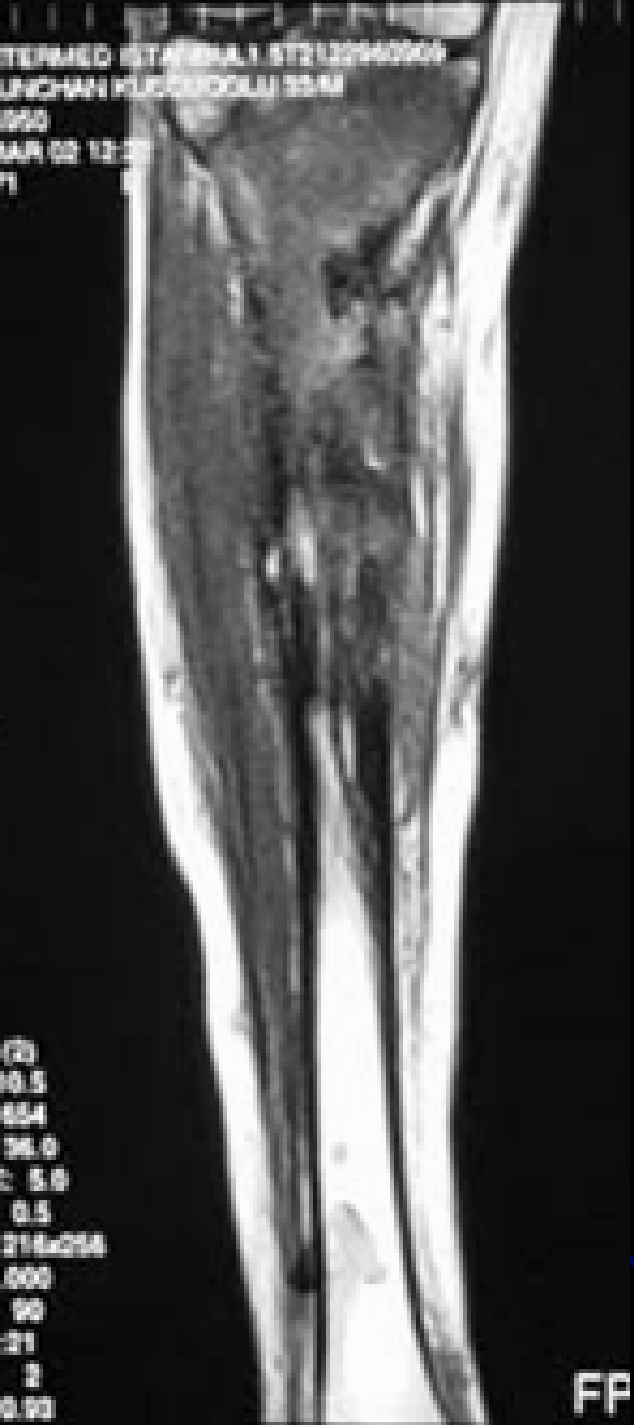- 18 hastada eksülsere yada geniş cilt infiltrasyonu olan sarkom
- 2 hastada tibia üst ucunda postirradiyasyon sarkomu
- 2 hastada modüler replasman protezi revizyonu



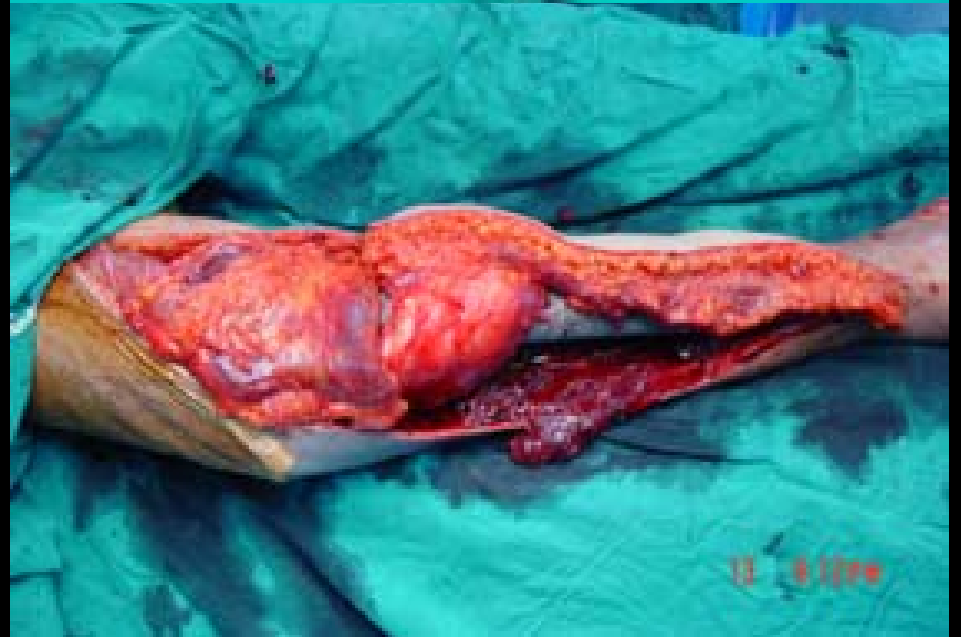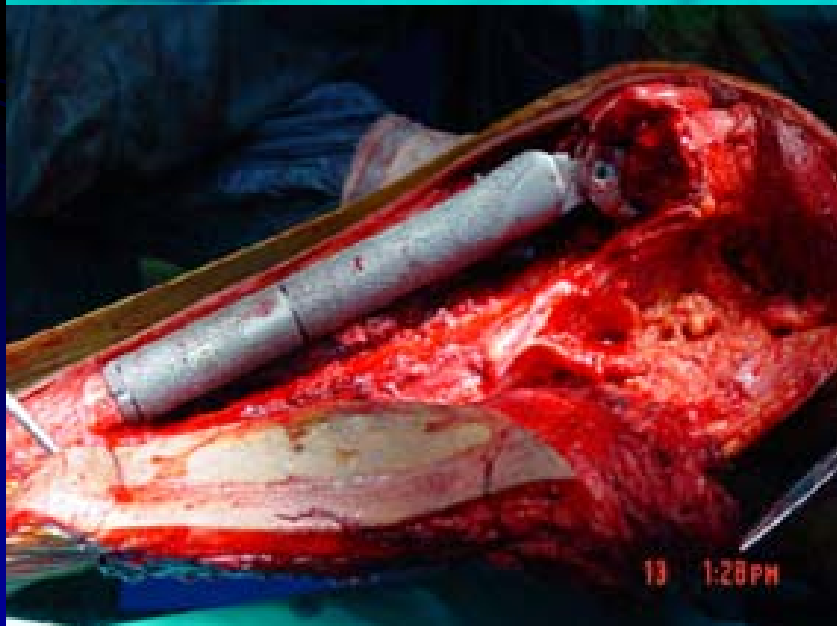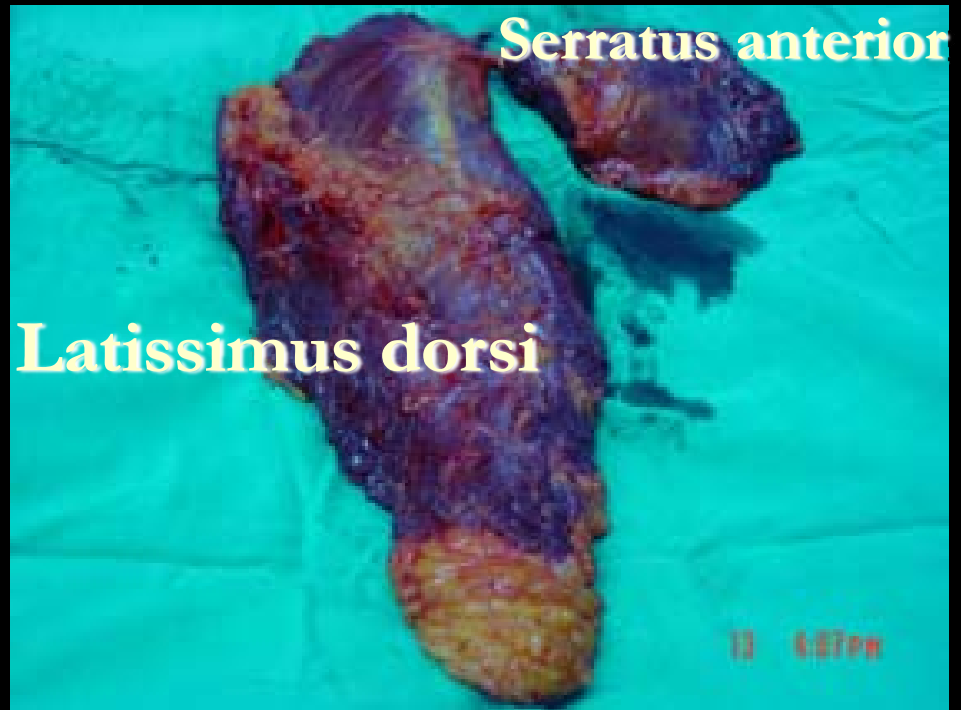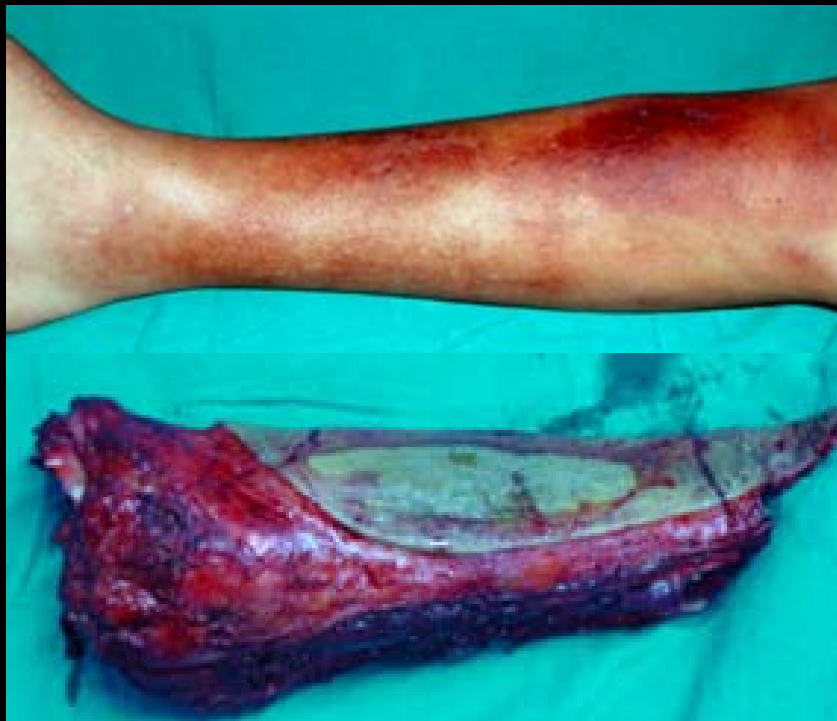Hastalar ve Yöntem

- 18 hastada eksülsere yada geniş cilt infiltrasyonu olan sarkom
- 2 hastada tibia üst ucunda postirradiyasyon sarkomu
- 2 hastada modüler replasman protezi revizyonu



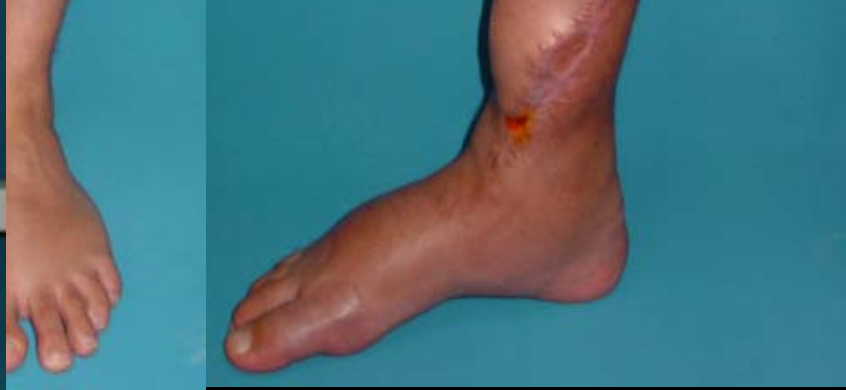
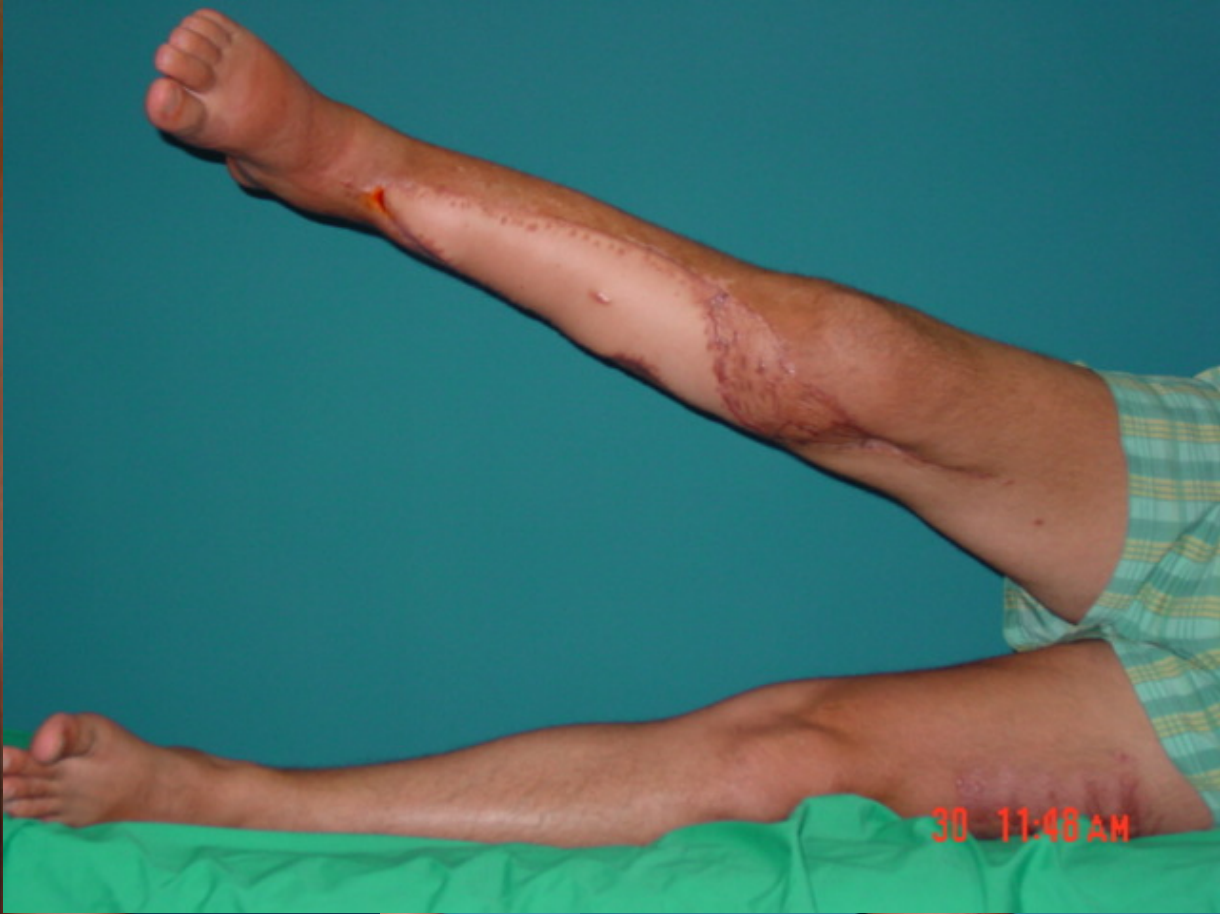
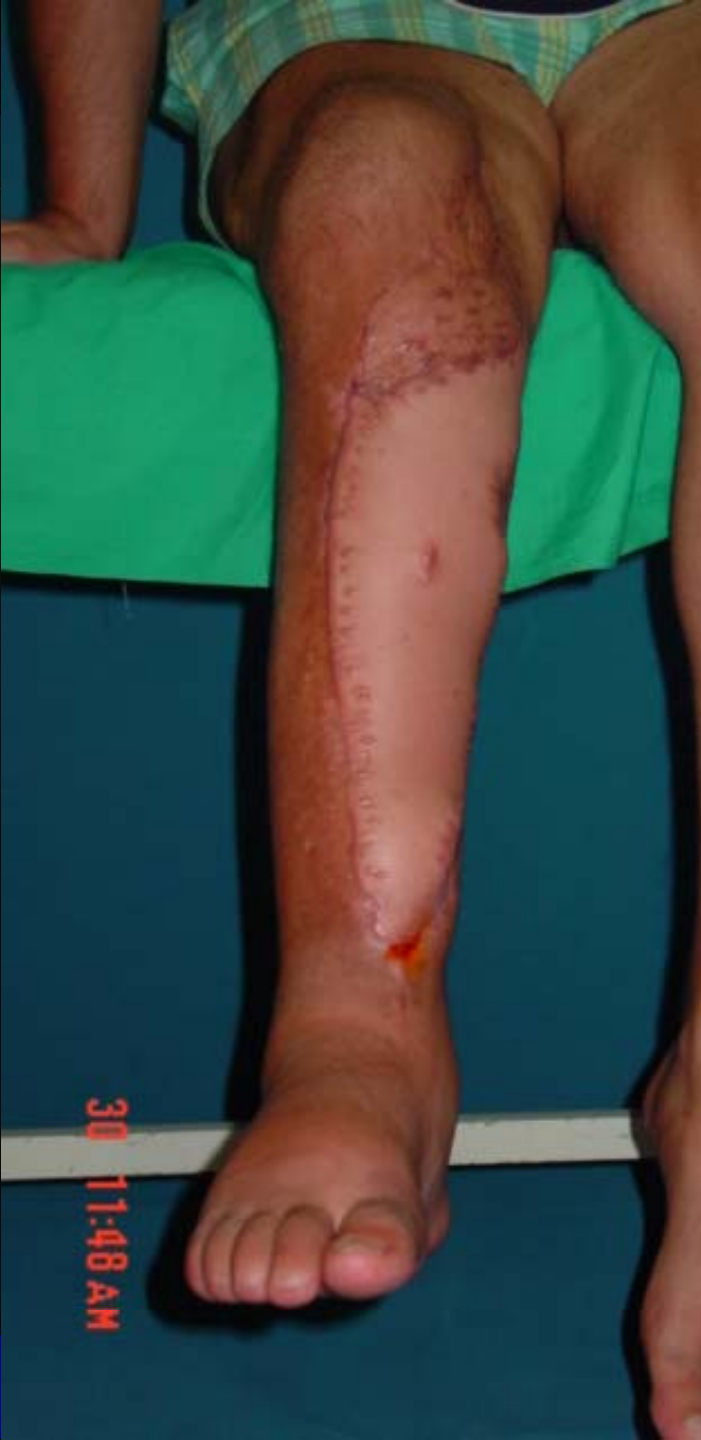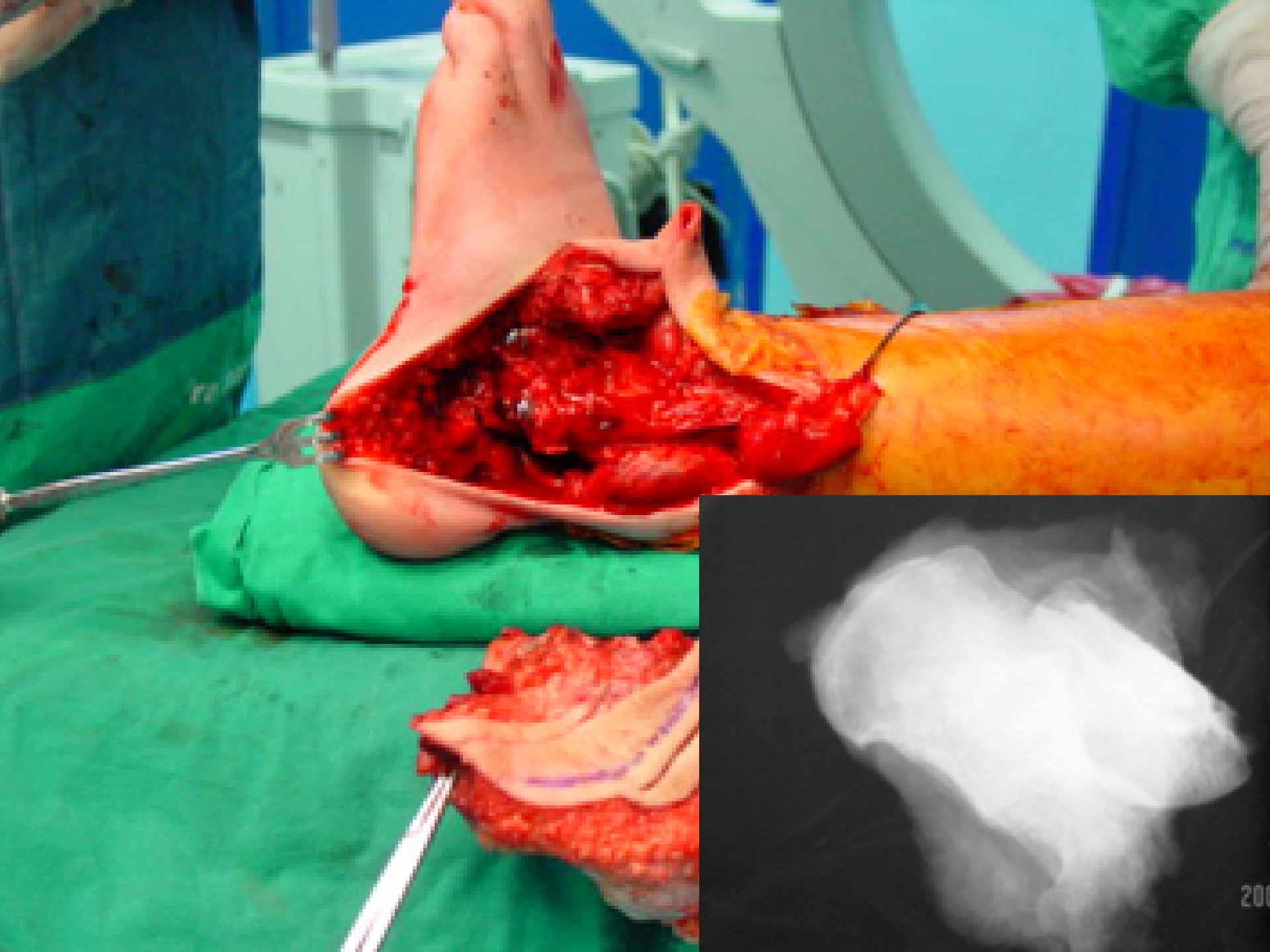
24 y, E
EWS -12 y
Post IRRS

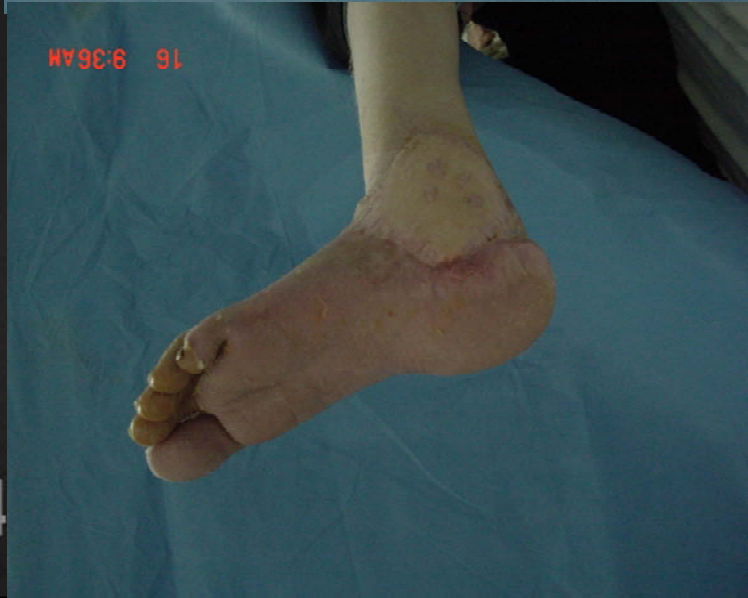
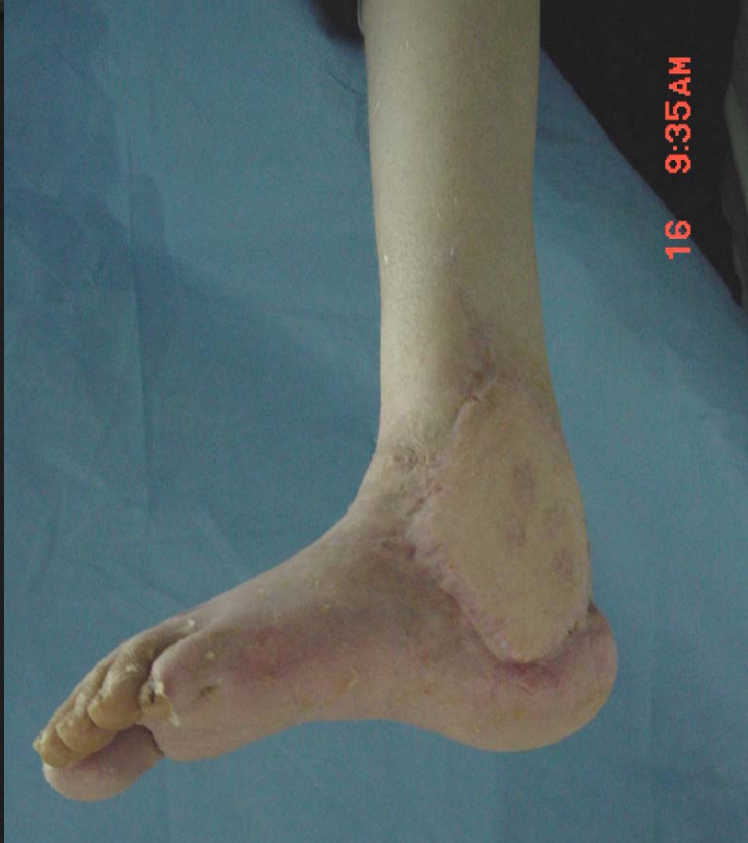
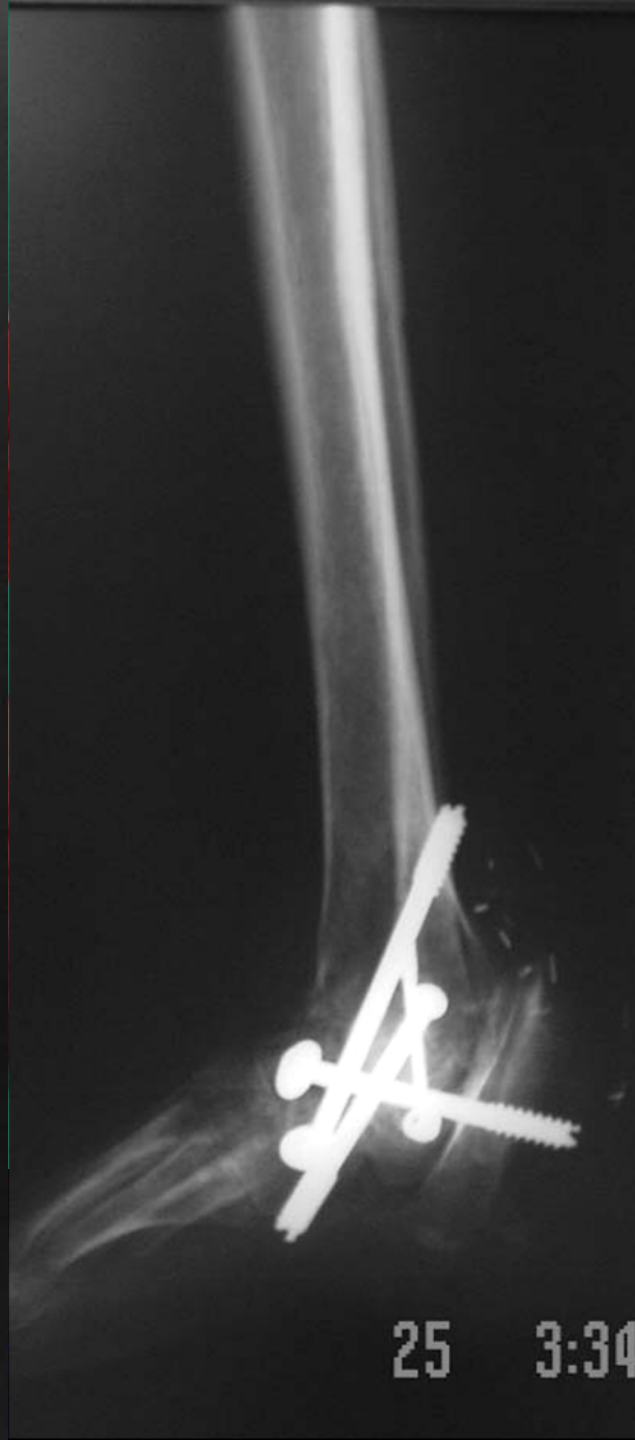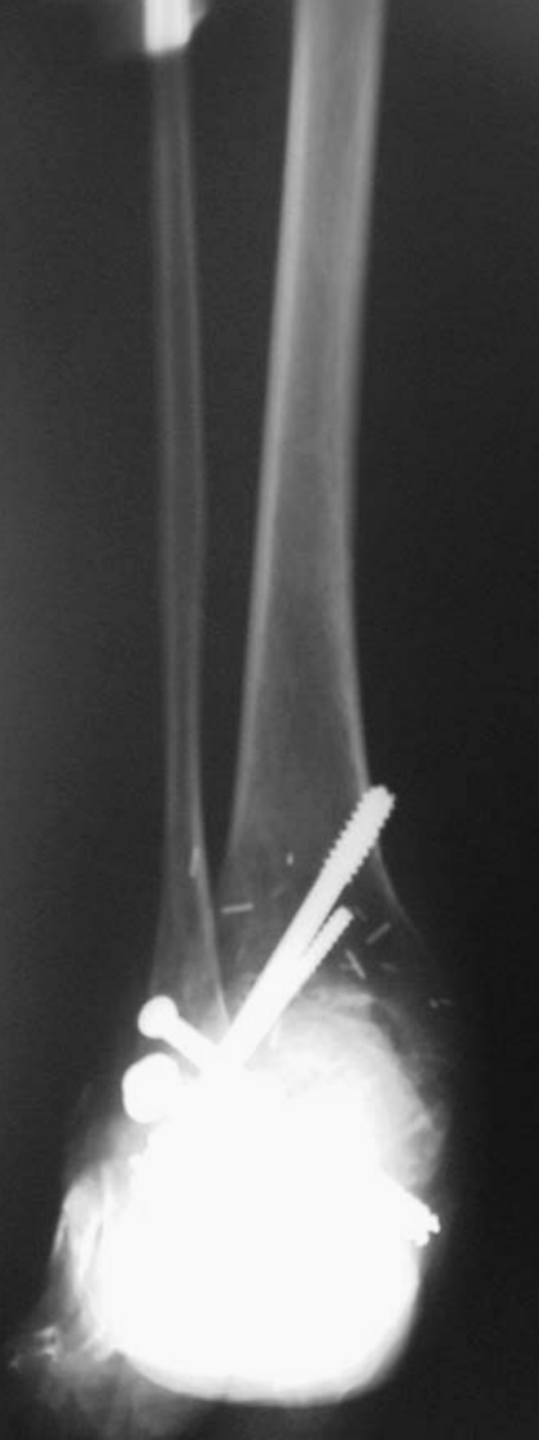Serratus anterior

Latissimus dorsi

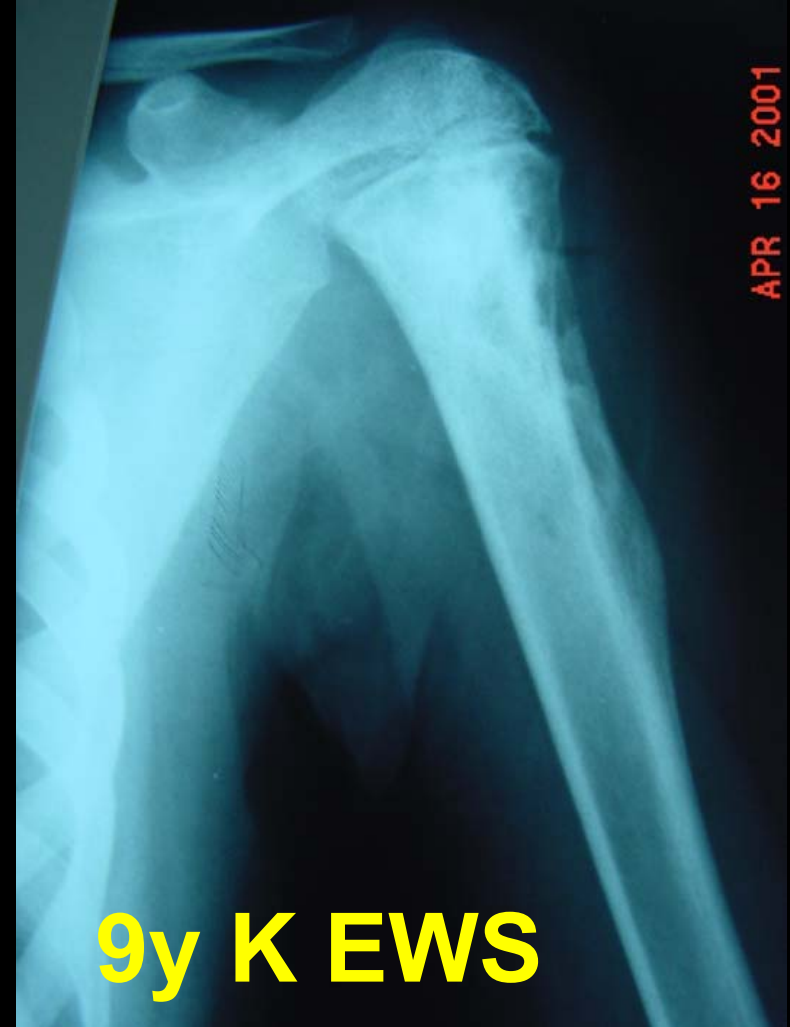


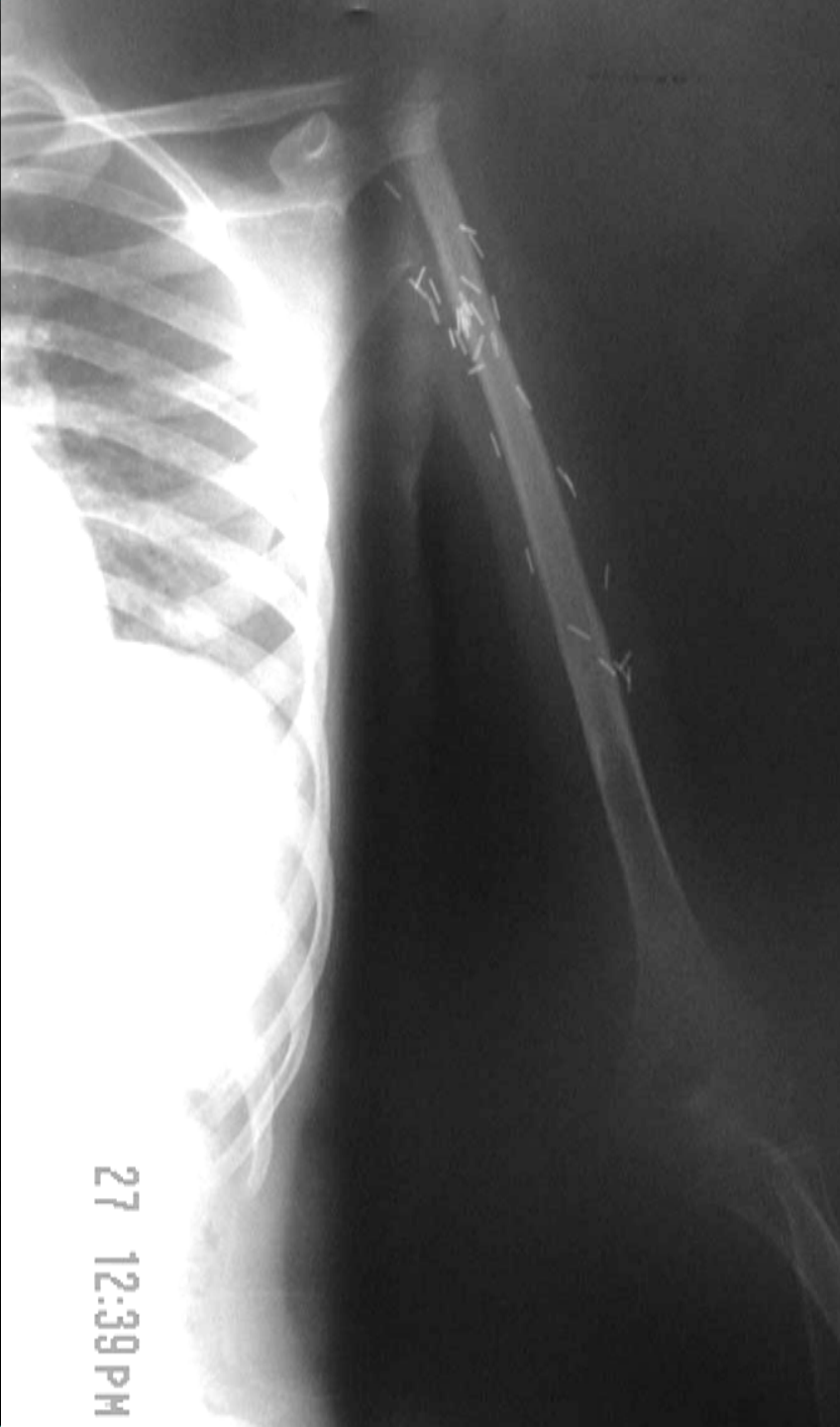
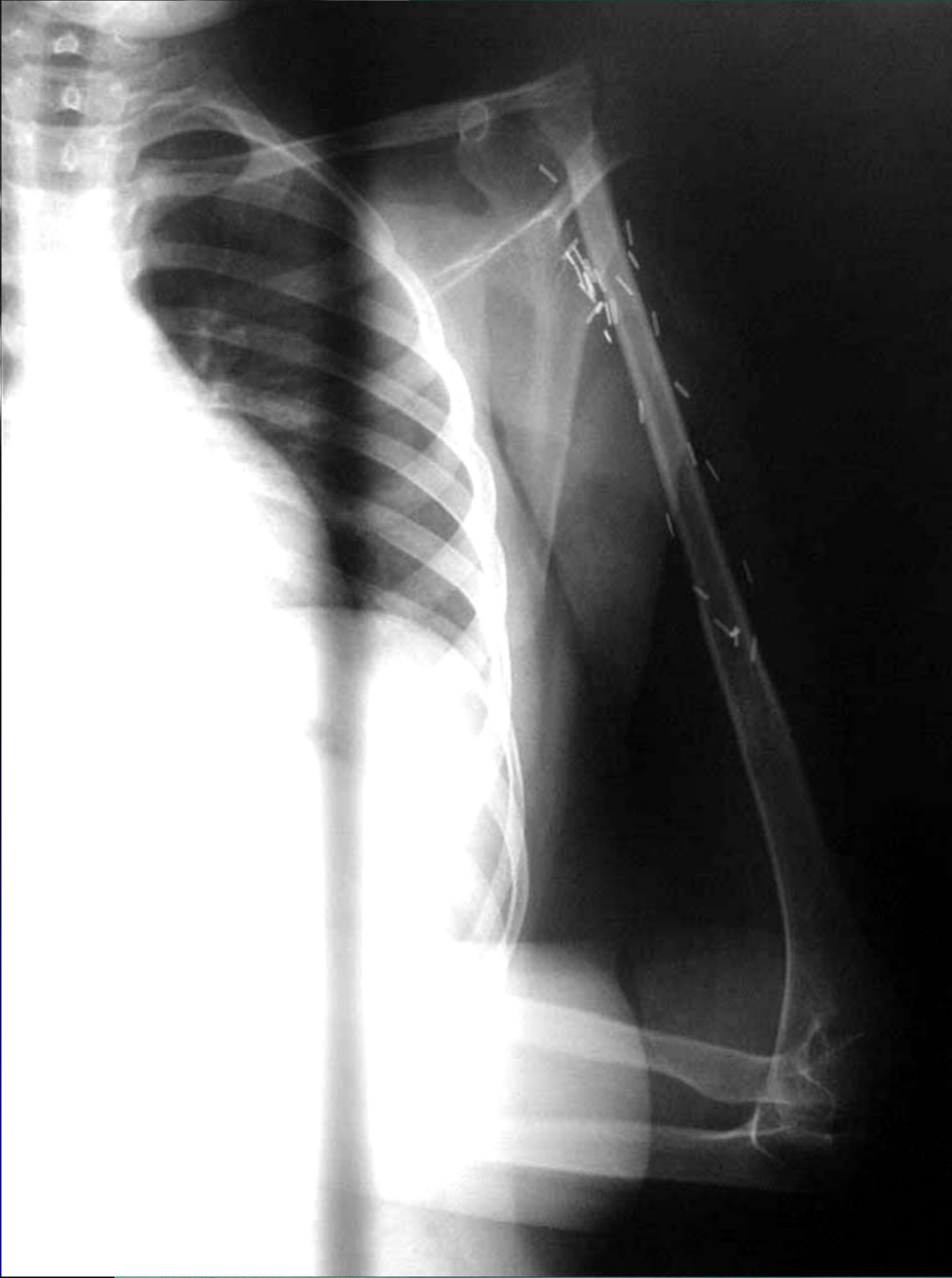

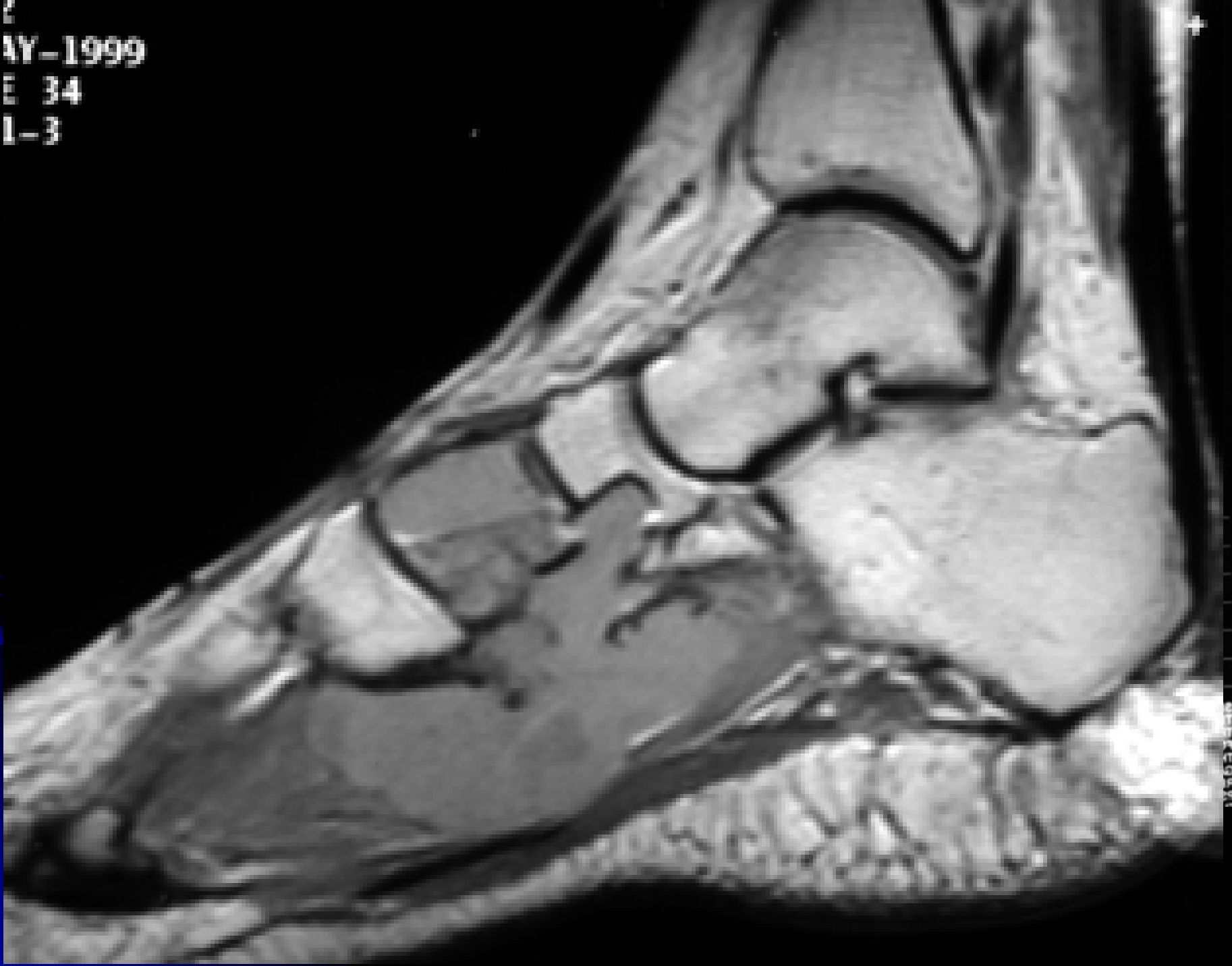
Hastalar ve Yöntem

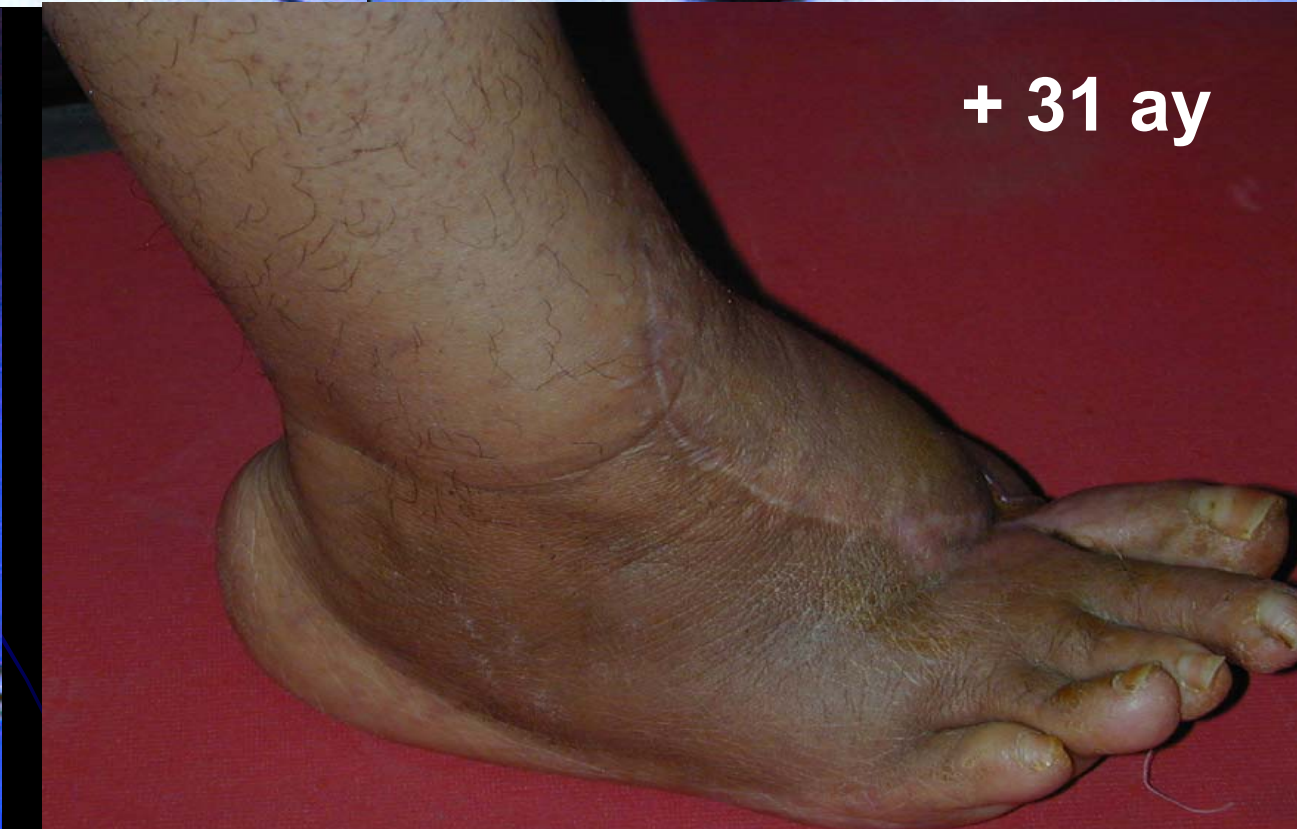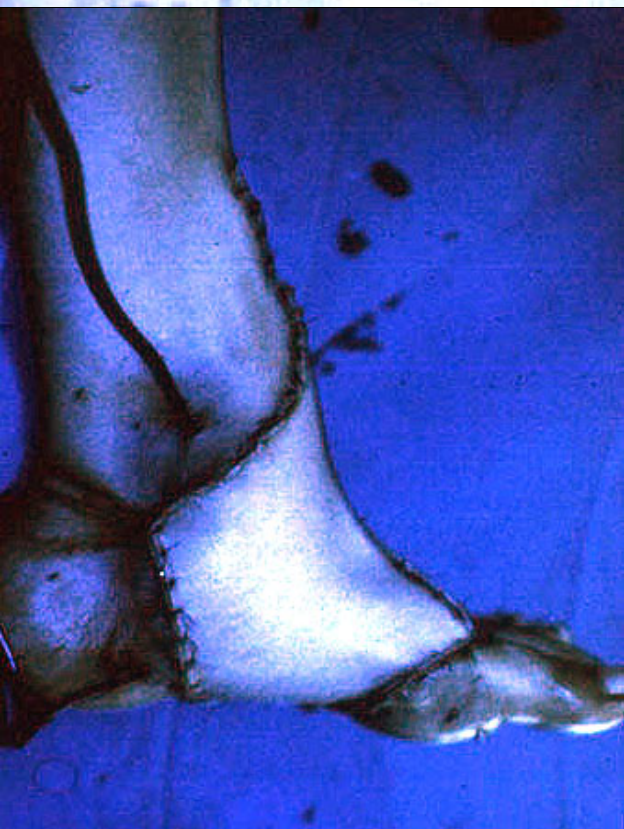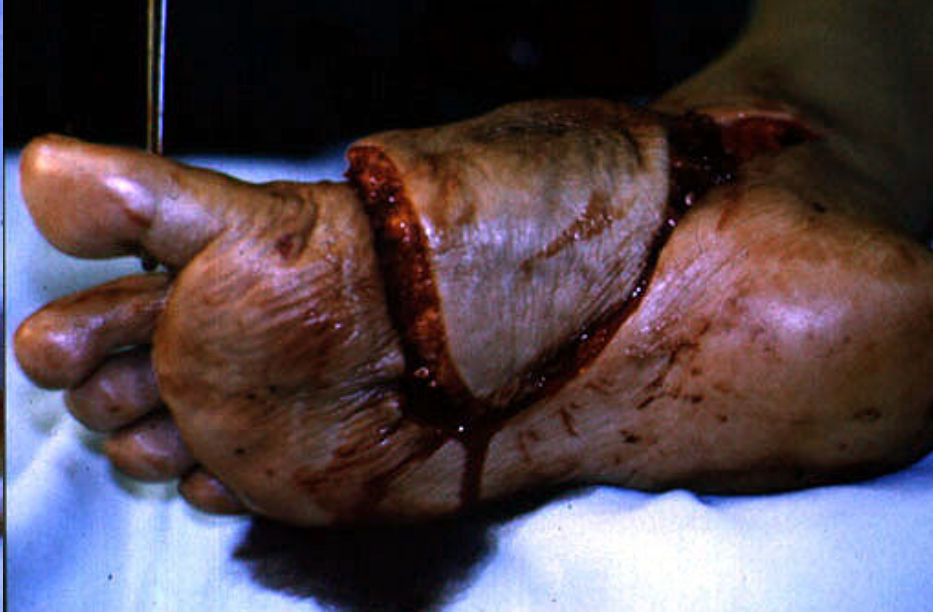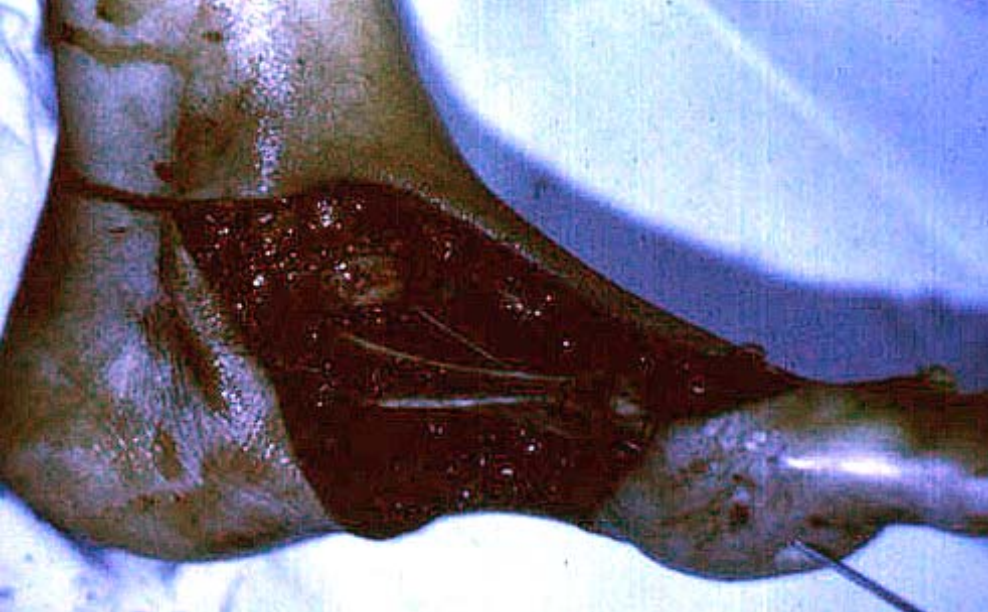- 10 serbest latissimus dorsi miyokutanöz flebi
- 2 serbest iliak kanat osteomiyokutanöz flebi
- 1 serbest fibula osteomiyokutanöz flebi
- 1 serbest radial önkol flebi
- 9 lokal ada flebi
- 7 hastada ek modüler endoprostetik rekonstrüksiyon





F
AY-1999
E 34
I-3





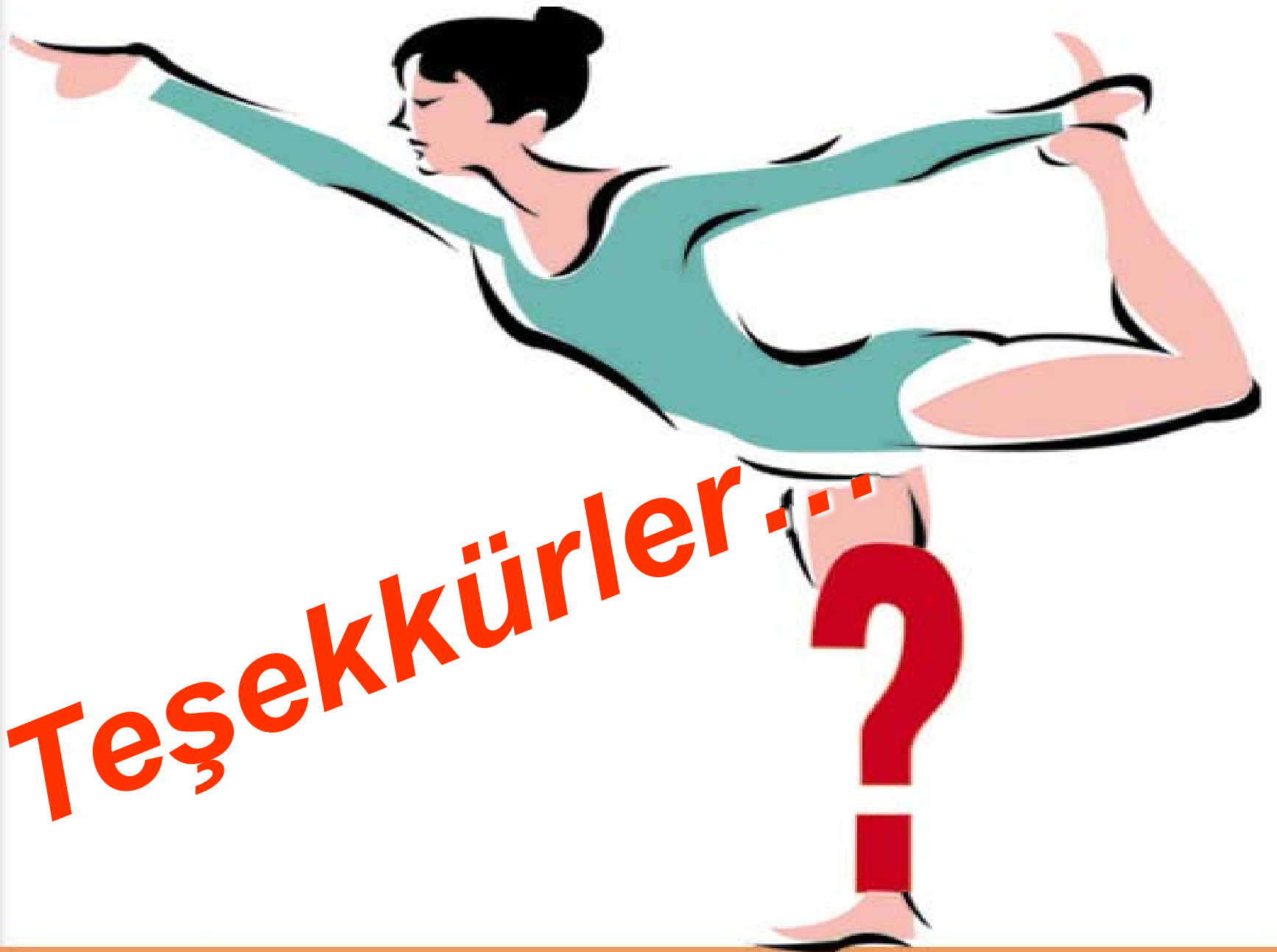+ 31 ay

Uzuv koruma...



AB

???



Teşekkürler ...